



ORIGINAL

Bilingual article English/Spanish

Rev Esp Podol. 2024;35(2):105-109

DOI: <http://dx.doi.org/10.20986/revesppod.2024.1710/2024>

## Ultrasound-guided percutaneous needle fasciotomy. Case series

### Fasciotomía percutánea ecoguiada con aguja. Serie de casos

Ana M.<sup>a</sup> Rayo Pérez, Rafael Rayo Martín, Rafael Rayo Rosado, and Raquel García de la Peña

Departamento de Podología. Universidad de Sevilla, Spain

#### Keywords:

Plantar fasciitis, ultrasonography, fasciotomy, needle, surgery.

#### Abstract

**Introduction:** Heel pain is a frequent reason for consultation in health clinics and a small percentage of them tend to become chronic, giving rise to complex conditions that require surgical treatment for resolution. One of these cases is plantar fasciitis or recalcitrant fasciosis.

**Patients and methods:** A series of cases of five patients with chronic plantar fasciitis in whom conservative treatment has failed are presented. All of them underwent an ultrasound-guided partial fasciotomy with a 14 G needle.

**Results:** After the intervention, a considerable reduction in pain was achieved, measured through a Visual Analog Scale (VAS), and in the thickness of the plantar fascia, quantified by ultrasound. A high satisfaction score on the Likert Scale was also achieved.

**Conclusion:** Ultrasound-guided percutaneous needle fasciotomy is an effective and simple technique for the treatment of recalcitrant fasciitis, allowing rapid functional recovery and with a low risk of associated complications.

#### Palabras clave:

Fascitis plantar, ecografía, fasciotomía, aguja, cirugía.

#### Resumen

**Introducción:** Las talalgias son un motivo frecuente de consulta en las clínicas sanitarias y un pequeño porcentaje de ellas tienden a cronificarse, dando lugar a cuadros complejos que requieren de tratamiento quirúrgico para su resolución. Uno de estos casos es la fascitis plantar o fasciosis recalcitrante.

**Pacientes y métodos:** Se exponen una serie de casos de diez pacientes con fascitis plantar crónica en los que ha fracasado el tratamiento conservador. A todos ellos se les realizó una fasciotomía parcial ecoguiada con aguja 14 G.

**Resultados:** Tras la intervención, se consiguió una reducción considerable del dolor, medido a través de una Escala Visual Analógica (EVA), y del grosor de la fascia plantar, cuantificado mediante ecografía. También se consiguió una puntuación alta de satisfacción en la Escala Likert.

**Conclusión:** La fasciotomía percutánea ecoguiada con aguja es una técnica eficaz y sencilla para el tratamiento de la fascitis recalcitrante, permitiendo una recuperación funcional rápida y con un riesgo bajo de complicaciones asociadas.

#### Introduction

Heel pain (talalgias) is a common reason for consultation and resolves in 90 % of cases within 10-12 months, but 10 % become chronic and develop into a complex condition, primarily involving plantar fasciitis<sup>1</sup>.

The fascia is a fibrous tissue band that extends from the posterior processes of the calcaneus to its distal insertion in the plantar

plate and plantar fat. It is part of the Achilles-Calcaneal-Plantar system and is involved in the development of the windlass mechanism, including functions such as controlling the collapse of the inner arch, reducing compressive forces on the inner column, and assisting the posterior tibial muscle in decelerating pronation<sup>2,3</sup>.

Fasciopathy is a degenerative process of the plantar fascia due to excessive traction at its proximal insertion, leading to heel pain, particularly on the first steps of the day (start-up pain) or after peri-

Received: 10-09-2024

Accepted: 11-11-2024



0210-1238 © The Authors. 2024.  
Editorial: INSPIRA NETWORK GROUP S.L.  
This is an Open Access paper under a Creative Commons Attribution 4.0 International License ([www.creativecommons.org/licenses/by/4.0/](http://www.creativecommons.org/licenses/by/4.0/)).

Corresponding author:

Ana M.<sup>a</sup> Rayo Pérez  
anarayo43@gmail.com

ods of rest. Risk factors for its development include prolonged sitting, reduced dorsal flexion of the hallux, repeated microtrauma, and biomechanics in pronation. Therefore, it is a common conditions in athletes, affecting around 5 % up to 15% of cases, especially in those performing repetitive actions like running<sup>4,6</sup>.

This condition affects adults aged 40-60 years, with bilateral involvement in 1 out of every 3 cases. It most frequently affects the medial area of the insertion of the central band of the plantar fascia, approximately 42 % of the time, and is diagnosed clinically, though it may be accompanied by several clinical tests, such as the Jack test to assess the integrity of the plantar fascia, the Barouk test to evaluate the relationship between triceps sural retraction and hallux limitus, or the Silfverskiöld test to assess posterior muscle retraction. It can also be confirmed using imaging modalities, such as ultrasound or magnetic resonance imaging, which allow visualizing the structural condition of the fascia and its relationship with the calcaneus<sup>3,4,7</sup>.

Plantar fasciitis requires a differential diagnosis from tendinitis of the common flexor muscle of the toes, Baxter’s neuropathy, tibial nerve neuropathy, bursitis, calcaneal disease, tumors, or Achilles disease<sup>1,5,8</sup>.

Conservative treatments include pharmacological therapy using analgesics and anti-inflammatory drugs, physical therapy such as functional bandaging, shock waves, diathermy, percutaneous intra-tissue electrolisis, regenerative therapy through platelet-rich plasma (PRP) injections, prolotherapy, and orthopedic treatments using plantar supports<sup>7,9,10</sup>.

However, when the condition becomes chronic (5 % up to 10 % of cases) and conservative treatments fail, a wide range of surgical options becomes available, including partial or total fasciotomy, either via open surgery or minimally invasive techniques, and arthroscopy. Minimally invasive techniques include fasciotomy with a Beaver 64 blade via a plantar approach, using 16 G or 18 G Nokor needles, and retractable scalpels. These techniques have evolved to incorporate ultrasound to provide a more precise and less invasive approach<sup>11-13</sup>.

Complications associated with these interventions are varied, but secondary flatfoot due to calcaneal stress fractures can occur. However, with the use of ultrasound, these complications have been significantly reduced<sup>4,6</sup>.

The mean recovery time for these surgical procedures is 7 months, as fascia healing is slow, especially if the patient intends to return to high-impact physical activities<sup>6,14</sup>.

### Patients and methods

A series of 10 cases in 9 patients surgically treated with percutaneous needle fasciotomy is presented, collected from May 2023 through May 2024 at Clínica Rayo, located in Arahál (Seville), as shown in Tables I and II.

Prior to performing the surgical technique, it was performed on a cadaveric model (Figure 1).

The surgical protocol begins with the administration of a 2 % mepivacaine ankle block, numbing the tibial and sural nerves to ensure complete foot anesthesia and enhance patient comfort during the procedure. Next, an ultrasound examination is performed, and with the help of a demographic pencil, the insertion and course of the plantar fascia are marked. A longitudinal ultrasound scan of the plantar fascia is performed, identifying the most distal point of the calcaneal cortex and the interface with fascia tissue as the deepest measurement point. The following point is directed perpendicularly toward a point established at the fascia-fat tissue interface.

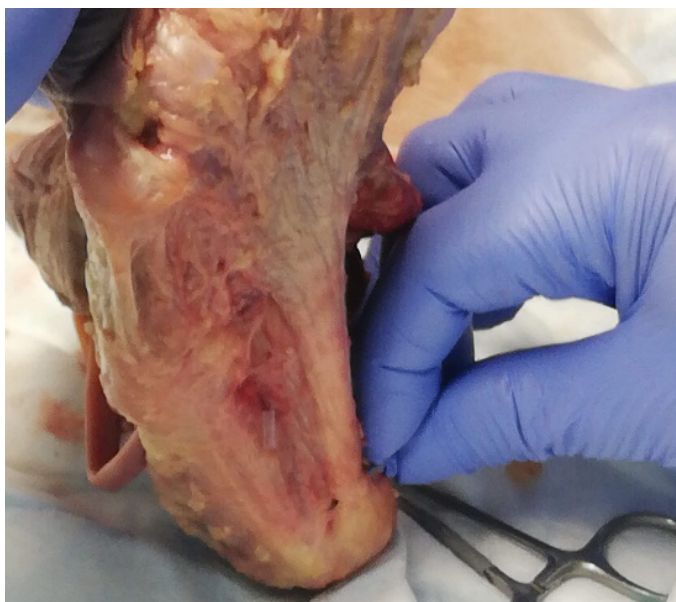
Once identified, a deep puncture is performed using a 21 G intramuscular needle at the fascia’s deepest interface with the flexor digitorum brevis, followed by a second puncture with a second 21 G needle in the more superficial fascia-fat tissue interface, making sure they are perpendicular to the fascia (Figure 2).

Once the fascia thickness and puncture zone in the medial foot area are defined, an incision is performed between the 2 guide needles using a 14 G needle, performing a “windscreen wiper” cut with

Case	Sex	Age	Laterality	Progression time (months)	Medical history	Previous treatments
1	Male	18	Right foot	14	Semi-professional athlete	Injections + Custom Orthotics
2	Male	18	Left foot	12	Semi-professional athlete	Injections + Custom Orthotics
3	Male	50	Right foot	24	No relevant history	Injections + Custom Orthotics + Physical Therapy
4	Male	36	Left foot	36	No relevant history	Injections + Custom Orthotics + Physical Therapy
5	Male	29	Left foot	25	No relevant history	Injections + Custom Orthotics + Physical Therapy
6	Male	47	Left foot	16	Amateur athlete	Injections + Custom Orthotics + Physical Therapy
7	Male	47	Right foot	14	Amateur athlete	Injections + Custom Orthotics + Physical Therapy
8	Male	37	Left foot	22	No relevant history	Injections + Custom Orthotics
9	Male	29	Left foot	10	Amateur athlete	Injections + Custom Orthotics + Physical Therapy
10	Male	43	Right foot	18	No relevant history	Injections + Custom Orthotics

**Table II. Follow-up data of treated patients**

Case	Pre-op eva	Pre-op ultrasound	Post-op eva 6 months	Post-op eva 12 months	Likert scale 6 months post	Ultrasound 6 months post
1	8	Thickness 0.91 cm	2	0	9	Thickness 0.53 cm
2	7	Thickness 0.72 cm	0	0	10	Thickness 0.47 cm
3	10	Thickness 1.4 cm	3	0	8	Thickness 0.60 cm
4	9	Thickness 0.83 cm	0	0	10	Thickness 0.51 cm
5	8	Thickness 0.97 cm	0	0	9	Thickness 0.42 cm
6	9	Thickness 0.59 cm	0	0	9	Thickness 0.58 cm
7	8	Thickness 0.92 cm	0	0	9	Thickness 0.43 cm
8	9	Thickness 0.76 cm	2	0	10	Thickness 0.51 cm
9	7	Thickness 0.91 cm	0	0	8	Thickness 0.55 cm
10	8	Thickness 1.04 cm	0	0	9	Thickness 0.57 cm

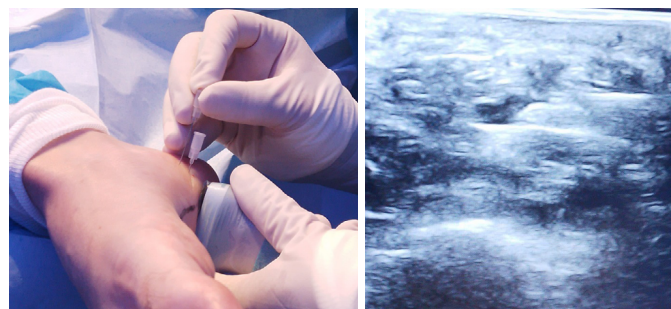


**Figure 1.** Surgical technique on a cadaver model.

the needle bevel while passively activating the windlass mechanism to maintain maximum tension in the plantar fascia. Afterward, the relaxation of the structure is checked, and the gesture is repeated until the desired stretch is achieved.

Post-surgery, a mild-to-moderate pain is expected, so oral analgesics (1 g paracetamol every 8 hours for 3 days) are prescribed. A bandage with gauze and a compression wrap is applied, and walking is restricted within the first week, with a splint placed to prevent weight bearing on the operated foot.

From week 2, controlled weight-bearing is allowed, and functional bandaging is applied to reinforce the plantar fascia area. One month later, posterior chain stretches and strengthening exercises begin. Two



**Figure 2.** Ultrasound-guided fasciotomy.

months later, proprioception exercises and light running are introduced. Finally, six months later, the patient can resume full physical activity.

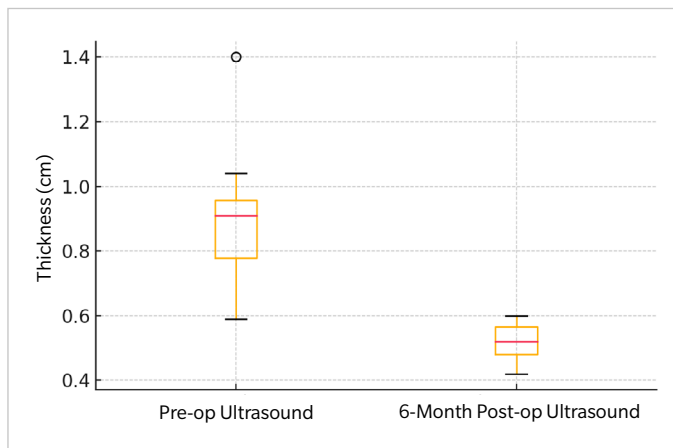
Measurements of plantar fascia thickness preoperatively and 6 postoperatively were made together with a measurement of pain with a Visual Analog Scale (VAS) during the preoperative, 6 and 12 months postoperatively. Finally, a satisfaction scale was made with a Likert type scale.

Results were presented by mean ± standar desviation for quantitative variables and simple percentages for cualitative variables.

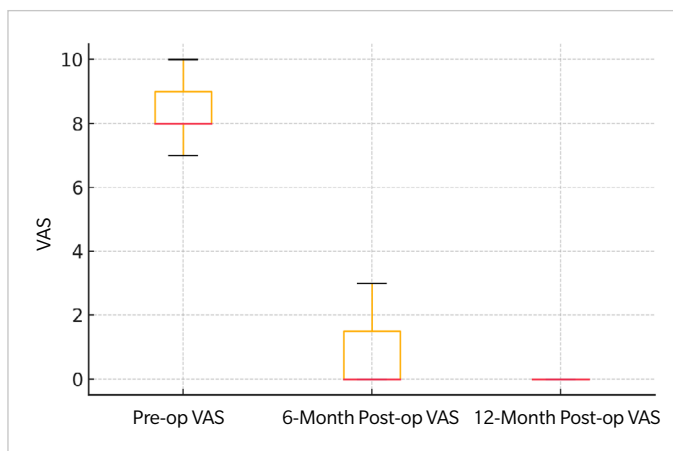
## Results

Ten males with chronic plantar fasciopathy in 9 patients with a mean age of 29.6 years and a > 19.1-month history of pain (SD, 7.41) are presented. One case was bilateral, and the rest, unilateral, with the left foot predominating (60 %). Conservative treatments included ultrasound-guided intralesional injections, administered every 21 days with 1.5 cc of MD collagen matrix, and resin foot supports with heel “cut-out” for pronation control and pressure offloading.

The ultrasound examination (Figure 3) revealed the presence of 2 patients with an acute rupture of the fascia due to chronic degen-



**Figure 3.** Foresplot: Evolution of the ultrasound thickness in the longitudinal axis of the plantar fascia.



**Figure 4.** Foresplot: Evolution of the subject's pain measured on the Visual Analog Scale (VAS).

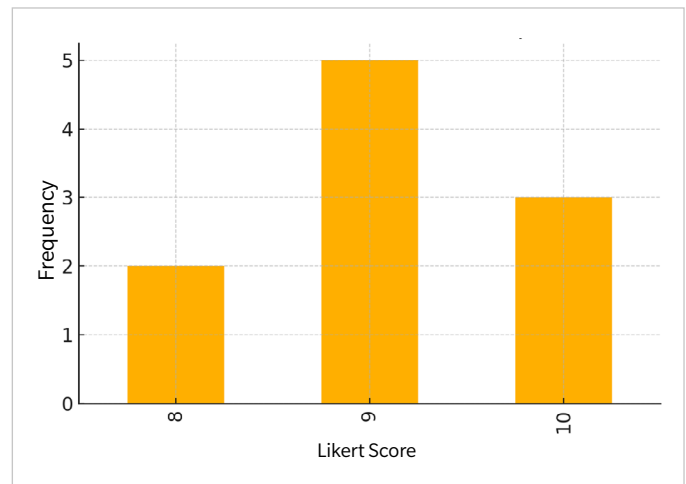
eration, with a mean fascia thickness of 0.966 cm before surgery, reduced to 0.506 cm after the procedure.

Regarding pain (Figure 4), the mean Visual Analog Scale (VAS) score dropped from 8.4 points down to 1 point at 6 months and 0 points at 12 months post-intervention.

Additionally, a satisfaction score of 9.1 points on the Likert Scale was obtained (Figure 5).

### Discussion

Plantar fasciitis is one of the most common causes of heel pain, characterized by inflammation and thickening of the plantar fascia, a tissue band connecting the heel to the toes<sup>7,11</sup>. While conservative therapies like orthotics and stretching exercises exist, some individuals do not achieve relief, particularly in chronic cases<sup>13,14</sup>. Minimally invasive surgery has emerged as a viable option for those who do not respond to other treatments<sup>8,10-12</sup>.



**Figure 5.** Foresplot: Evolution of the subject's satisfaction with the procedure measured on the Likert scale.

One of the advancements made in surgical techniques is ultrasound-guided plantar fascia release, which enables more precise interventions with lower risks. This technique, as noted by Marcos et al.<sup>15</sup> (2016), uses a needle to release the fascia without requiring a large incision. By using ultrasound guidance, the specialist can target the compromised area while avoiding damage to surrounding tissues, resulting in significant pain reduction.

Recent studies support this ultrasound-guided technique. A review of 107 cases by Iborra et al.<sup>16</sup> (2021) demonstrated considerable pain reduction 2 years after the procedure, measured by the VAS. Moreover, patients showed functional improvement, indicating that this minimally invasive, closed technique reduces the risk of complications such as infections and promotes faster recovery.

Percutaneous tenotomy is another technique, also ultrasound-guided. According to Bermejo et al.<sup>17</sup> (2022), this procedure is safe and effective, allowing partial release of the plantar fascia through small controlled microlesions without the need for a large incision. These microlesions stimulate the body's natural healing ability, reducing inflammation and promoting long-term recovery. The study conducted by Bermejo found that patients experienced a reduction in fascia thickness and sustained symptom improvement.

A broader analysis by Shomal Zadeh et al.<sup>18</sup> (2023) further supports the effectiveness of ultrasound-guided percutaneous tenotomy for chronic fasciopathy. This meta-analysis confirmed that the technique not only alleviates pain in the short term but also improves functionality and quality of life in the long run, making it a valid, low-risk alternative to conventional treatments.

Among newer approaches is ultrasound-guided fasciotomy along with the injection of an amniotic membrane allograft, studied by Nakagawa et al.<sup>19</sup> (2022). This technique combines fascia release with amniotic membrane injection, which promotes healing and reduces inflammation. Patients who received this combined therapy reported significant pain reduction and faster recovery vs those who only had fasciotomy.

In our study, we evaluated a total of 10 patients with long-standing chronic plantar fasciitis, applying ultrasound-guided collagen injec-

tions and customized foot orthotics designed to reduce pressure on the heel and correct foot pronation. The results showed a significant reduction in fascia thickness, from a mean 0.966 cm down to 0.506 cm after treatment. Regarding pain relief, patients' VAS scores dropped from 8.4 down to just 1 point at the 6-month follow-up, and they reported no pain at the 12-month follow-up. Moreover, the mean satisfaction score was 9.1 points, suggesting high patient satisfaction.

This study is consistent with other research and supports the use of ultrasound-guided techniques for the treatment of chronic plantar fasciitis, demonstrating that they are effective procedures that are well tolerated by patients.

In conclusion, from results of the present study ultrasound-guided percutaneous fasciotomy with a needle is an effective and simple technique for the treatment of refractory fasciitis, allowing for rapid functional recovery with a low risk of associated complications.

#### Conflicts of interest

None declared.

#### Funding

None declared.

#### Authors' contributions

Study conception and design: AMRP.

Data collection: AMRP, RRM, RRR.

Creation, drafting, and preparation of the initial draft: RRM.

Final review: RRR, RGP.

#### References

- Monteagudo M, de Albornoz PM, Gutierrez B, Tabuenca J, Álvarez I. Plantar fasciopathy: A current concepts review. *EFORT Open Rev.* 2018;3(8):485-93. DOI: 10.1302/2058-5241.3.170080.
- Al-Boloushi Z, López-Royo MP, Arian M, Gómez-Trullén EM, Herrero P. Minimally invasive non-surgical management of plantar fasciitis: A systematic review. *J Bodyw Mov Ther.* 2019;23(1):122-37. DOI: 10.1016/j.jbmt.2018.05.002.
- Yuan Y, Qian Y, Lu H, Kou Y, Xu Y, Xu H. Comparison of the therapeutic outcomes between open plantar fascia release and percutaneous radiofrequency ablation in the treatment of intractable plantar fasciitis. *J Orthop Surg Res.* 2020;15(1):55. DOI: 10.1186/s13018-020-1582-2.
- Campillo-Recio D, Ibañez M, Jimeno-Torres E, Comas-Aguilar M, Mendez-Gil A, Jimeno-Torres JM, et al. Two-Portal Endoscopic Plantar Fascia Release: Step-by-Step Surgical Technique. *Arthrosc Tech.* 2020;10(1):e15-e20. DOI: 10.1016/j.eats.2020.09.002.
- MacRae CS, Roche AJ, Sinnott TJ, O'Connell NE. What is the evidence for efficacy, effectiveness and safety of surgical interventions for plantar fasciopathy? Protocol for a systematic review. *BMJ Open.* 2019;9(10):e031407. DOI: 10.1136/bmjopen-2019-031407.
- Vajapey S, Ghenbot S, Baria MR, Magnussen RA, Vasileff WK. Utility of Percutaneous Ultrasonic Tenotomy for Tendinopathies: A Systematic Review. *Sports Health.* 2021;13(3):258-64. DOI: 10.1177/1941738120951764.
- Campillo-Recio D, Ibañez M, Martín-Dominguez LA, Comas-Aguilar M, Fernández-Morales M, Alberti-Fito G. Local Percutaneous Radiofrequency for Chronic Plantar Fasciitis. *Arthrosc Tech.* 2021;10(5):e1315-e1320. DOI: 10.1016/j.eats.2021.01.031.
- Malahias MA, Cantiller EB, Kadu VV, Müller S. The clinical outcome of endoscopic plantar fascia release: A current concept review. *Foot Ankle Surg.* 2020;26(1):19-24. DOI: 10.1016/j.fas.2018.12.006.
- Feng SM, Song RL, Wang AG, Sun QQ, Zhang SC. Endoscopic Partial Plantar Fasciotomy via 2 Medial Portals vs Mini-Open Procedure for Refractory Plantar Fasciitis. *Foot Ankle Int.* 2021;42(4):458-63. DOI: 10.1177/1071100720964805.
- De Prado M, Cuervas-Mons M, De Prado V, Golanó P, Vaquero J. Does the minimally invasive complete plantar fasciotomy result in deformity of the Plantar arch? A prospective study. *Foot Ankle Surg.* 2020;26(3):347-53. DOI: 10.1016/j.fas.2019.04.010.
- Colberg RE, Ketchum M, Javier A, Drogosz M, Gomez M, Fleisig GS. Clinical Outcomes of Percutaneous Plantar Fasciotomy Using Microdebrider Coblation Wand. *Foot Ankle Int.* 2020;41(2):187-92. DOI: 10.1177/1071100719883266.
- Hasegawa M, Urits I, Orhurhu V, Orhurhu MS, Brinkman J, Giacomazzi S, Foster L, Manchikanti L, Kaye AD, Kaye RJ, Viswanath O. Current Concepts of Minimally Invasive Treatment Options for Plantar Fasciitis: a Comprehensive Review. *Curr Pain Headache Rep.* 2020;24(9):55. DOI: 10.1007/s11916-020-00883-7.
- MacRae CS, Roche AJ, Sinnott TJ, O'Connell NE. What is the evidence for efficacy, effectiveness and safety of surgical interventions for plantar fasciopathy? A systematic review. *PLoS One.* 2022;17(5):e0268512. DOI: 10.1371/journal.pone.0268512.
- Johannsen F, Konradsen L, Herzog R, Rindom Krogsgaard M. Plantar fasciitis treated with endoscopic partial plantar fasciotomy-One-year clinical and ultrasonographic follow-up. *Foot (Edinb).* 2019;39:50-54. DOI: 10.1016/j.foot.2019.02.002.
- Marcos A, Villanueva M, Barrett S. Ultrasound-Guided Plantar Fascia Release with Needle: A Novel Surgical Technique. *Open J Orthoped.* 2016;06(07):159-70. DOI: 10.4236/ojo.2016.67024.
- Iborra A, Villanueva M, Sanz-Ruiz P, Martín A, Noriega C. A novel closed technique for ultrasound-guided plantar fascia release with a needle: review of 107 cases with a minimum follow-up of 24 months. *J Orthop Surg Res.* 2021;16(1):153. DOI: 10.1186/s13018-021-02302-y.
- Bermejo M, Lucar-López G, Ballester-Alomar M, Córdoba-Fernández A, Martínez-Souto C, Villamizar M, Guevara-Noriega KA. Tenotomía longitudinal ecoguiada para el tratamiento de fasciitis plantar. Nota técnica y revisión sistemática. *Acta Ortop Mex.* 2022;36(4):252-6. DOI: 10.35366/109812.
- Shomal Zadeh F, Shafiei M, Shomalzadeh M, Pierce J, Thurlow PC, Chalian M. Percutaneous ultrasound-guided needle tenotomy for treatment of chronic tendinopathy and fasciopathy: a meta-analysis. *Eur Radiol.* 2023;33(10):7303-20. DOI: 10.1007/s00330-023-09657-2.
- Nakagawa H, Sung K, Ashkani-Esfahani S, Waryasz G, May T, Sussman WI. Plantar fasciitis: a comparison of ultrasound-guided fasciotomy with or without amniotic membrane allograft injection. *Regen Med.* 2022;17(12):931-40. DOI: 10.2217/rme-2022-0094.