



ORIGINAL

Artículo bilingüe español/inglés

Rev Esp Podol. 2019;30(1):3-9

DOI: 10.20986/revesspod.2019.1538/2019

## Innervation patterns of superficial peroneal nerve and sural nerve in the proximal dorsal aspect of the foot. An anatomical cadaveric study

*Variaciones de inervación del nervio peroneo superficial y sural en la zona proximal del pie. Estudio anatómico cadavérico*

Francisco Casado Hernández<sup>1</sup>, Ángel Manuel Orejana García<sup>2</sup> y Javier Pascual Huerta<sup>3</sup>

<sup>1</sup>Clínica Principium, Soria. <sup>2</sup>Universidad Complutense de Madrid, Madrid. <sup>3</sup>Clínica del Pie Elcano, Bilbao

### Keywords:

Superficial peroneal nerve, sural nerve, lateral dorsal cutaneous nerve, intermediate dorsal cutaneous nerve, medial dorsal cutaneous nerve, anatomic variations, foot innervation, cadaveric study.

### Abstract

**Introduction:** There are important variations in the innervation of the dorsum of the foot and leg regarding the distribution of the superficial peroneal nerve (SPN) and sural nerve (SN). Although several patterns have been described, literature has not reach a consensus on the percentages of those patterns.

**Materials and methods:** A cadaveric anatomical study was performed on 49 fresh frozen lower limbs. The study had a transversal descriptive design. A systematic dissection was carried out on dorsum of the foot of the specimens and the estimated prevalence of anatomic variations taking as reference 3 patterns of distribution was calculated. Measurements of perforation of the SPN and SN were also taken.

**Results:** The patterns of distribution of SPN were: 48.89 % (CI 95 % from 33.70 % to 64.08 %) had a type I distribution, where SPN pierces deep fascia and then it divides into medial dorsal cutaneous nerve (MDCN) and intermediate dorsal cutaneous nerve (IDCN); 33.33 % (CI 95 % from 19.01 % to 47.66 %) had a type II distribution, where SPN bifurcates and then pierces the fascial layer separately as MDCN and IDCN; 17.78 % (CI 95 % from 6.16 % to 29.39 %) had a type III distribution, where SPN pierces deep fascia, courses identical as MDCN and IDCN is absent.

**Conclusion:** The present study gives data on the pattern of distribution of the innervation of the dorsum of the foot and leg and its percentages in a sample of 49 feet. The information reported has important implications in surgical and anesthetic approaches of the foot and ankle.

### Palabras clave:

Nervio peroneo superficial, nervio sural, nervio cutáneo dorsal lateral, nervio cutáneo dorsal intermedio, nervio cutáneo dorsal medial, variaciones anatómicas, inervación del pie, estudio cadavérico.

### Resumen

**Introducción:** Existen variaciones importantes en cuanto a la distribución y territorio de inervación del nervio peroneo superficial (NPS) y nervio sural (NS) en la cara dorsolateral del pie y la pierna, habiendo sido descritos diferentes patrones de inervación. La literatura no es concluyente en cuanto a los porcentajes de presentación de estos patrones.

**Material y métodos:** Se realizó un estudio cadavérico sobre 49 piezas anatómicas con un diseño descriptivo transversal. El estudio se realizó sobre piezas recientemente descongeladas que se diseccionaron de forma sistemática. Se estimó la prevalencia de variaciones anatómicas con respecto a tres patrones de distribución y se tomaron mediciones de las perforaciones del NPS y del NS respecto al maléolo peroneo.

**Resultados:** La distribución encontrada fue: un 48,89 % (IC 95 % de 33,70 % a 64,08 %); presentaba una distribución tipo I (el NPS perfora la fascia profunda y posteriormente se divide en nervio cutáneo dorsal intermedio [NCDI] y nervio cutáneo dorsal medial [NCDM]), un 33,33 % (IC 95 % de 19,01 % a 47,66 %) presentaba una distribución tipo II (el NPS se divide en el compartimento profundo y el NCDI y NCDM perforan la fascia como estructuras independientes) y un 17,78 % (IC 95 % de 6,16 % a 29,39 %) presentaba una distribución tipo III (el NPS perfora la fascia profunda y sigue el recorrido del NCDM y el NCDI está ausente).

**Conclusión:** El presente estudio aporta datos de patrones de inervación dorsal del pie en una muestra de 49 piezas cadavéricas. Esta información puede resultar de utilidad en los abordajes quirúrgicos y anestésicos del pie.

Received: 09-02-2019

Accepted: 19-03-2019



0210-1238 © Los autores. 2019.  
Editorial: INSPIRA NETWORK GROUP S.L.  
Este es un artículo Open Access bajo la licencia CC Reconocimiento 4.0 Internacional  
([www.creativecommons.org/licenses/by/4.0/](http://www.creativecommons.org/licenses/by/4.0/)).

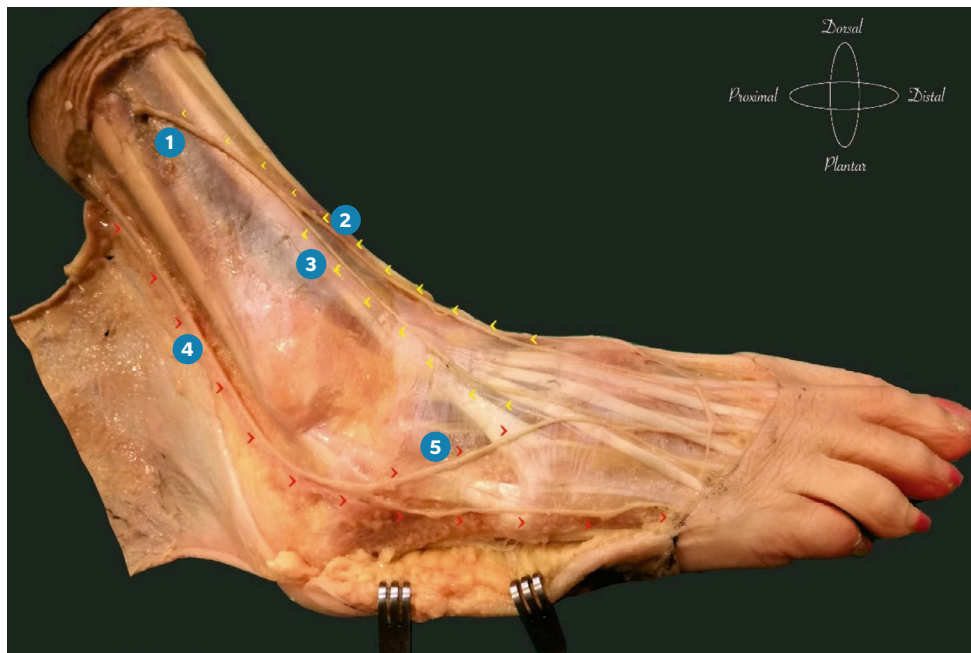
Correspondence:

Javier Pascual Huerta  
[javier.pascual@hotmail.com](mailto:javier.pascual@hotmail.com)

## INTRODUCTION

The superficial peroneal nerve and the sural nerve are two of the main nerves that provide dorsal innervation to the foot. The classic description of the course and innervation territory of these nerves describes the superficial peroneal nerve piercing the deep fascia (*fascia cruris*) and becoming superficial on the anterolateral side of the distal third of the leg to later divide into a medial and lateral branch. The medial branch is the medial dorsal cutaneous nerve that divides again giving a medial branch for the medial aspect of the first toe and a lateral branch for the second intermetatarsal space. The lateral branch of the superficial peroneal nerve is the intermediate dorsal cutaneous nerve that supplies innervation to the third and fourth intermetatarsal spaces<sup>1-3</sup> (Figure 1). On the other hand, the sural nerve becomes superficial in the posterior part of the leg and descends distally in a slightly lateral direction to cross the ankle between the Achilles tendon and the lateral malleolus. During its course it gives multiple branches that innervate the lateral and posterior aspect of the foot and the leg and continues distally its terminal branch until innervating the lateral aspect of the fifth toe<sup>2,3</sup> (Figure 1). However, despite this classic description shown in Figure 1 there is a great variability in the pattern of dorsal innervation of the foot from one individual to another and this pattern is only present in half of the individuals<sup>4-6</sup>, which may compromise surgical approaches and distal anesthetic techniques of the foot and ankle.

The classic work done by the Anatomical Society of Great Britain and Ireland based on the dissection of 229 foot and published in 1891<sup>4</sup>, described a total of 12 different innervation patterns for the dorsum of the foot that are shown in Figure 2 providing statistical information of its frequency. This work, which is maintained today as the main reference to describe the variability of the dorsal innervation of the foot, showed that, generally speaking, when the territory innervated by the sural nerve increases, that of the intermediate dorsal cutaneous nerve decreases and vice versa. Approximately 25 % of the specimens examined in this study showed absence of the intermediate dorsal cutaneous nerve, with the sural nerve being the nerve supplying the territory of the intermediate dorsal cutaneous nerve intermediate on the dorsum of the foot. Likewise, in the last 25 years several studies<sup>7-13</sup> have shown great variability in the frequency of the innervation patterns of the dorsal area of the foot. This is especially striking in the percentage of presence and / or absence of the intermediate dorsal cutaneous nerve and the replacement of its innervation territory by the sural nerve. A recent systematic review and meta-analysis of the bifurcation and perforation patterns of the deep fascia of the superficial peroneal nerve (665 lower limbs)<sup>13</sup> showed that the absence of intermediate dorsal cutaneous nerve occurred in only 1.8 % of specimens, so that the work of the Anatomical Society of Great Britain and Ireland could be overestimating this parameter (which rates it by 25 %). Therefore it is so evident the need of more anatomical stu-



**Figure 1.** Anatomy of superficial peroneal nerve and sural nerve in anterolateral aspect of the leg and foot. Type I pattern of Tomaszewski et al.<sup>13</sup>.

1. Superficial peroneal nerve piercing Deep fascia in the anterolateral aspect of the leg; 2. Medial dorsal cutaneous nerve; 3. Intermediate dorsal cutaneous nerve; 4. Sural nerve. 5. Anastomotic branch of sural nerve to dorso medial cutaneous nerve.

90 REPORT OF COMMITTEE OF COLLECTIVE INVESTIGATION OF

TABLE V.—Variations in the Distribution of the Cutaneous Nerves on the Dorsum of the Foot. Number of Feet examined, 229.

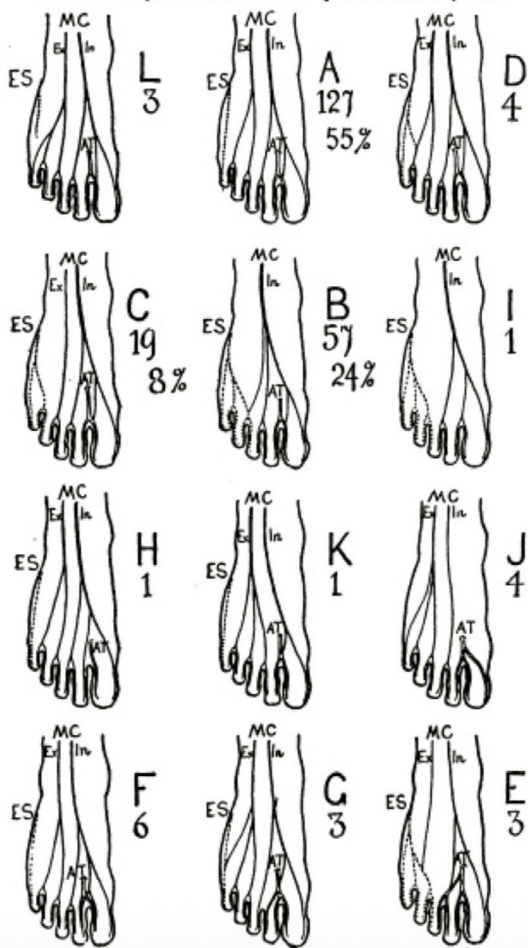


Figure 2. Original Table obtained from Anatomical Society of Great Britain and Ireland en: *Thompson A. Second Annual Report of the Committee of Collective Investigation on the Distribution of Cutaneous Nerves on the Dorsum of the Foot. J Anat Physiol. 1891;26[Part 1]:89-101. Table V.*

dies describing the frequencies of the anatomical variations of these nerves.

The main objective of this work is to assess the innervation pattern of the dorsolateral area of the foot in a sample of cadaveric specimens, paying special attention to the presence or absence of the intermediate dorsal cutaneous nerve and its replacement of its innervation territory by the sural nerve. The secondary objective is to make a measurement taking the lateral malleolus as reference for the location of the point of perforation of the deep fascia of the superficial peroneal nerve and / or its terminal branches (medial and intermediate dorsal cutaneous nerve) and also of the sural nerve with respect to the peroneal malleolus. These measurements could help when setting points of reference to perform

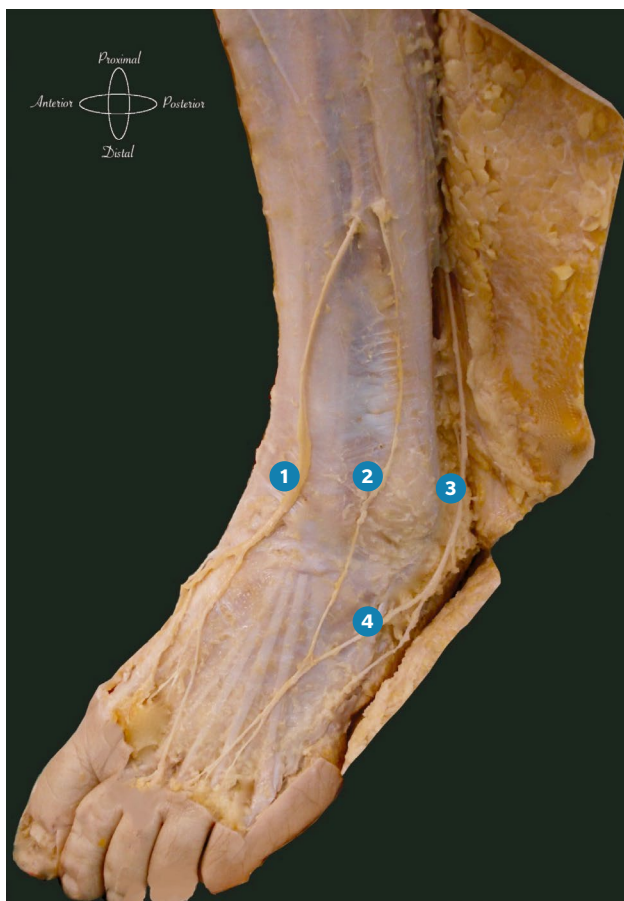anesthetic blockages in the foot or to plan the locations of safer incisions that do not compromise the nerve structures.

**MATERIAL AND METHODS**

The present work is a cadaverous study with a purely descriptive transversal design. For the writing of this article, the recommended AQUA (Anatomical Quality Assurance checklist) list was followed in the EQUATOR network as a guide for reporting original anatomical studies<sup>14</sup>.

The study was performed on freshly thawed cadaveric pieces that were dissected systematically. The cadaveric pieces of the study were being used for the realization of an anatomical dissection seminar for podiatrists that was carried out in a dissection room over a full weekend and that encompassed the entire anatomical dissection of the foot and ankle. Data of the present study was taken from the cadaver pieces used in 4 different seminars that were carried out in the following places and dates: Valencia (February 2017 and January 2018), Pamplona (November 2018) and Oviedo (December 2018). They used all the anatomical pieces which the seminar was held with. None of the anatomical pieces of the study showed evidence of previous surgical interventions in the foot or leg that compromised the data collection of the present study. The present study was carried out respecting the international recommendations on research of the Declaration of Helsinki of the World Medical Association<sup>15</sup>. The dissection was carried out by removing carefully the skin and subcutaneous tissue from the lateral and dorsal side of the leg and foot to expose the deep fascia to that level. During the dissection, the sural nerve, the intermediate dorsal cutaneous nerve and the medial dorsal cutaneous nerve were located, avoiding as much as possible the distortion of the nerve structures. For this, the nerve course was followed during the dissection proximally to its point of perforation of the deep fascia and distally to the digits taken care of not disrupting its natural course without mobilizing them and only separating the fat around the nerve for a better visualization of it.

Once the nerves were identified and their course correctly delimited, the pattern of perforation and division of the superficial peroneal nerve in the leg was noted following the classification proposed by Tomaszewski et al.<sup>13</sup> that establishes 3 patterns of superficial peroneal nerve division: 1) Type I: The superficial peroneal nerve perforates the deep fascia and later divides into medial dorsal cutaneous nerve and intermediate dorsal cutaneous nerve (Figure 1); 2) Type II: The superficial peroneal nerve is divided into medial dorsal cutaneous nerve and intermediate dorsal cutaneous nerve in the deep face of the leg before perforating the deep fascia and later the two nerves perforate the deep fascia as two independent structures (Figure 3); 3) Type III: The superficial peroneal nerve perforates the deep fascia and continues its course in a similar manner to the medial dorsal cutaneous nerve and the intermediate dorsal cutaneous nerve is absent. In this innervation pattern, the innervation territory of the



**Figure 3.** Type II innervation pattern of Tomaszewski et al.<sup>13</sup>. Note that superficial nerve is bifurcated in medial and intermediate dorsal cutaneous nerves before perforation of the Deep fascia. Both nerves pierce independently the Deep fascia in the anterior compartment of the leg.

1. Medial dorsal cutaneous nerve; 2. Intermediate dorsal cutaneous nerve; 3. Sural Nerve; 4. Anastomotic Branch from the sural nerve to the intermediate dorsal cutaneous nerve.

intermediate dorsal cutaneous nerve is supplied by the sural nerve (Figure 4).

At the same time, the following measurements were taken in the sagittal plane with the foot and leg from a lateral position, the ankle at 90° and taking as reference the most distal point of the lateral malleolus: 1) distance between the most distal point of the lateral malleolus to the point of perforation of the peroneal nerve superficially in the deep fascia in the type I pattern of Tomaszewski et al.<sup>13</sup> or to the point of perforation of the medial and intermediate dorsal cutaneous nerves in the type II pattern of Tomaszewski et al.<sup>13</sup>; b) distance between the most distal point of the lateral malleolus to the dividing point of the superficial peroneal nerve in the intermediate dorsal cutaneous nerve and the medial dorsal cutaneous nerve (only in the type I pattern of Tomaszewski et al.<sup>13</sup>); c) distance between the most distal point of the lateral malleolus to the sural nerve distally following the

longitudinal axis of the leg (Figure 5). All measurements and assessments were made by the same investigator (JPH). For the data collection in each foot included in the study, the distribution pattern and the measurements made from the lateral malleolus were drawn on a foot diagram that was later translated to a data table. To make the measurements, a ruler was used in millimeters. A descriptive analysis of the data obtained measurements was carried out and the percentages for the qualitative variables as well as the means and the standard deviations for the quantitative variables were calculated. The confidence interval was calculated for 95 % of the measurements taken.

## RESULTS

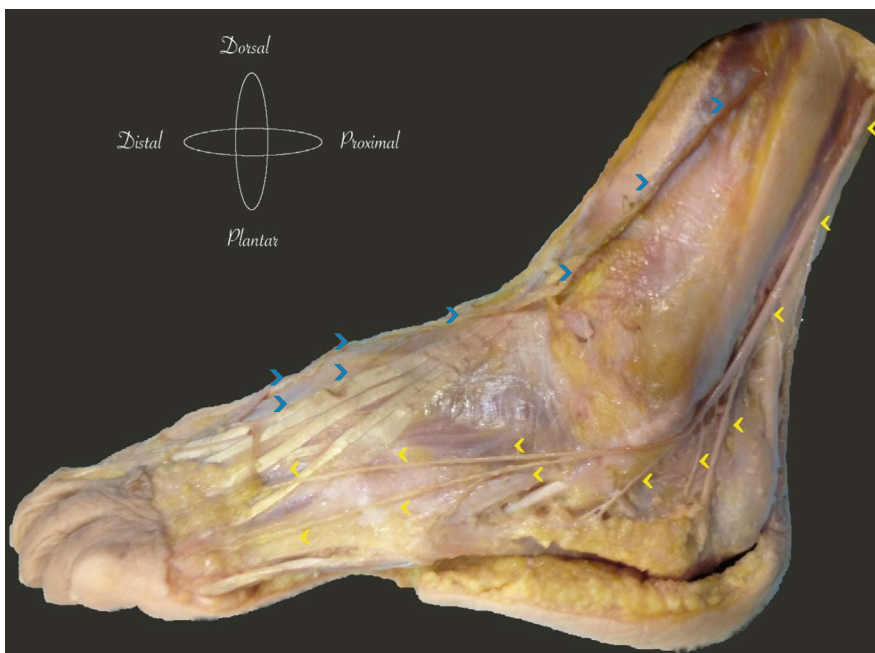
A total of 49 anatomical pieces (feet) were included in the study. The laterality of the feet studied was 30 feet right (61.22 %) and 19 feet left (38.77 %). The data referring to the sex and race of the specimens could not be obtained.

The distribution of the superficial peroneal nerve found was as follows: 22 cases (48.89 %; CI 95% from 33.70 % to 64.08 %) of the studied specimens presented a type I distribution, 15 of the cases (33.33 %; 95% CI from 19.01 % to 47.66 %) of the studied specimens presented a type II distribution and only 8 cases (17.78 %; CI 95% from 6.16 % to 29.39 %) of the specimens studied had a type III distribution. In 4 of the cases, the innervation pattern could not be identified through dissection due to technical errors in the same or because the cadaveric piece was severed very distally and did not allow the evaluation of its innervation pattern between type I and type II in the proximal area. Finally, Table I collects the results of the measurements obtained in the specimens studied with the average and 95 % confidence intervals.

## DISCUSSION

The superficial structures of the dorsum of the foot present a complex and highly variable innervation from one individual to another. The studies on the dorsal innervation of the foot have shown important variations regarding the distribution and innervation territory of the intermediate dorsal cutaneous nerve and sural nerve in the dorsolateral aspect of the foot and leg, although the percentages vary widely from one study to another without a clear consensus in this regard. Several studies estimate the absence of the intermediate dorsal cutaneous nerve between 10 %<sup>7</sup> and 24-35 %<sup>4,5,9</sup>, while other studies estimate it at 0 %<sup>10-12</sup> with a recent meta-analysis from Tomaszewski et al. in which this variation is estimated at 1.8 % with a 95 % CI from 0 % to 4.9 %<sup>13</sup>.

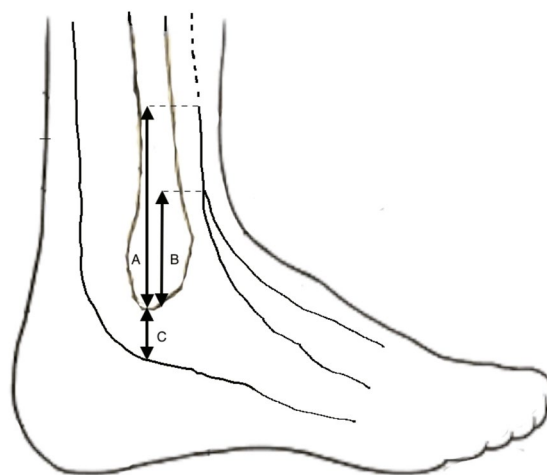
The present study has shown a percentage of incidence, taking the innervation pattern of Tomaszewski et al.<sup>13</sup> of approximately half of cases (48.89 %, 95 % CI of 33.70 % to 64.08 %) of Type I pattern in which the superficial peroneal nerve perforates



**Figure 4.** Type III innervation pattern of Tomaszewski et al.<sup>13</sup>. Note how superficial peroneal nerve follow the trajectory of the medial dorsal cutaneous nerve [blue arrows] with absence of intermediate dorsal cutaneous nerve. Sural nerve [yellow arrows] give branches for the innervation territory of intermediate dorsal cutaneous nerve.

the deep fascia and subsequently divides into medial dorsal cutaneous nerve and intermediate dorsal cutaneous nerve (Figure 1), one third of cases (33.33 %, 95 % CI of 19.01 % to 47.66 %) of type II pattern in which the superficial peroneal nerve is divided into intermediate dorsal cutaneous nerve and medial dorsal cutaneous nerve in the anterior deep compartment of the leg and pierces the fascia as two independent structures (Figure 3) and a 17.78 % (CI 95 % of 6.16 % to 29.39 %) of type III pattern with absence of intermediate dorsal cutaneous nerve and whose innervation territory is supplied by the sural nerve (Figure 4). These results are quite similar to those reported in other studies regarding the presence of the type I pattern<sup>4,10,11</sup> that estimate its frequency slightly higher than 50 %. The results of the present study support this data. In this context it is important to point out that although most of the classic anatomical texts describe only this pattern to describe the innervation of the dorsum of the foot<sup>1-3</sup>, this pattern occurs only in half of the studied specimens, being quite common to find anatomical variations to this description.

The sural nerve is clinically important because it is frequently used to perform nerve conduction tests, for biopsy in neuromuscular diseases such as hereditary sensory-motor neuropathy and even used as a nerve graft in plastic and reconstructive surgery. This nerve presents a great variety in its formation and its distribution on the dorsal of the foot. In the opinion of the authors of the present manuscript, the role of the sural nerve on the dorsum of the foot is much wider than that described in classical literature as only innervating the lateral aspect of the fifth finger. The present study has shown that in 17.78 % (95 % CI of 6.16 % to 29.39 %) of the cases there is an absence of the intermediate dorsal cutaneous nerve and its territory is supplied by the sural nerve (Figure 4). However, the results of



**Figure 5.** Measurements taken to the specimens of the study. A: Distance in the leg axis from the most distal point of the lateral malleolus to the perforation point of superficial peroneal nerve in the deep fascia. B: Distance in the leg axis from the most distal point of the lateral malleolus to the bifurcation point of the deep peroneal nerve into medial and intermediate dorsal cutaneous nerve. C: Distance in the leg axis from the most distal point of the lateral malleolus to the sural nerve.

the present study are somewhat lower with respect to the presence of the type III pattern, than those described by Thompson et al.<sup>4</sup> with 24 %, Solomon et al.<sup>5</sup> with 35 % and Aktan-Ikiz and Urcerler<sup>9</sup> with 26.7 % although they support the idea that this anatomical variation could be present in a significant percentage of the population and not assume a marginal variation as assumed by the meta-analysis from Tomaszewski et al. which

**Table I. Descriptive data of the measurements of the study**

	Cases	Mean (cm)	SD (cm)	CI (95%)	
				Inferior Limit (cm)	Superior Limit (cm)
Distance from lateral malleolus to piercing point of superficial peroneal nerve (Type I)	32	9.81	4.40	8.22	11.40
Distance from the lateral malleolus to the dividing point of the superficial peroneal nerve (Type I)	22	5.05	2.67	3.86	6.23
Distance from the lateral malleolus to the piercing point of the medial dorsal cutaneous nerve (Type II)	13	7.20	6.05	3.54	10.85
Distance from the lateral malleolus to the piercing point of the intermediate dorsal cutaneous nerve (Type II)	13	7.53	3.22	5.58	9.47
Distance from lateral malleolus to sural nerve distally (following axis of the leg)	46	1.94	0.41	1.82	2.06

Cm: centimeters; SD: Standard Deviation; CI (95%): 95 % confidence interval

estimates its frequency in 1.8 %<sup>13</sup>. In addition, and although the present study did not measure this aspect, it is common the presence of an anastomosis between the sural nerve and the intermediate dorsal cutaneous nerve (Figure 1 and Figure 2) in more than half the population<sup>16</sup>. Jong and cols.<sup>17</sup> studied the origin and course of the sural nerve in 110 cases and found the sural nerve giving innervation to the 5<sup>th</sup>, 4<sup>th</sup> toes and medial aspect of the 3<sup>rd</sup> toe in 53.2 % of cases and to the 5<sup>th</sup> and 4<sup>th</sup> toe in 33.3 % of cases. All these data suggest that the sural nerve has a more relevant role in the innervation of the dorsum of the foot than the classically described and is not limited only to the lateral aspect of the fifth toe.

The measurements obtained in the present study of the perforation pattern of the intermediate dorsal cutaneous nerve in the type I pattern (48.89 %) have shown that the perforation point is located between 8.22 cm and 11.40 cm (95 % IC) from the most distal point of the lateral malleolus. These data could be comparable to those obtained in other studies that measured the same parameter with the same reference points. Blair & Botte<sup>10</sup> cite the distance of the perforation point of the superficial peroneal nerve with the ankle (not with the distal point of the lateral malleolus) by 12.3 cm; Cánovas et al.<sup>8</sup> reports the distance with respect to the lateral malleolus at 11 cm, Sayli et al. at 10.41 cm<sup>11</sup> and Solomon et al. in 9.1 cm<sup>5</sup>. The results of the present study agree with these data and it seems that the confidence interval created (between 8.22 cm and 11.40 cm from the tip of the lateral malleolus) could be a good reference point to find the point of perforation of the superficial peroneal nerve in the fascia cruris and it could be a point to be used as a reference in the anesthetic blocks of the foot. However, it is interesting to remember that according to our study this pattern occurs only in type I and type III and not in type II where the dorsal cutaneous nerves and medial dorsal cutaneous nerves perforate the fascia independently. In the last case (type II pattern), the distance calculated from the lateral malleolus to the perforations to the intermediate

and medial dorsal cutaneous nerves is much more variable, as indicated by the standard deviations and the confidence intervals calculated. The reason for this variability is possibly due to the compartment where both nerves are at the time of piercing. It has been described that perforation of the intermediate dorsal cutaneous nerve can be performed from the anterior compartment of the leg or from the lateral compartment either from a position anterior to the fibula or even from a posterior position (lateral compartment)<sup>10,11,18</sup>, aspect that it was not analyzed in the present study. The different positions from where the perforation of both nerves occur is more variable and more difficult to reproduce in the type II pattern. However, in the present study the perforation of the fascia cruris of the intermediate dorsal cutaneous nerve is more proximal than that of the medial dorsal cutaneous nerve in the type II pattern (Figure 2), although the distance of both perforations with respect to the peroneal malleolus was quite similar. Regarding the measurement of the sural nerve, the present study calculated the distance from the distal tip of the lateral malleolus to the sural nerve following the longitudinal axis of the fibula. This distance obtained a value of 1.94 cm (95 % CI from 1.82 cm to 2.06 cm). A meta-analysis published by Ramakrishnan et al. in 2015 on the anatomical variations in the formation and course of the sural nerve<sup>19</sup>, also described the vertical distance the distal tip of the lateral malleolus to the sural nerve using 6 studies (185 lower limbs). The value reported was of 1.53 cm (SD = 0.56). Although the data of the present study are slightly different from those calculated by Ramakrishnan et al. it seems that between 1.5 cm and 2 cm distal to the peroneal malleolus would be a good location for the sural nerve, which could be used as a point of reference for the anesthetic block of the foot. However, clinical studies with anesthetic blocks in this location would be necessary to verify this hypothesis.

There are limitations associated with the present study and its results should be analyzed with caution. First, it is possi-

ble that the race and sex of the study specimens may impact the distribution patterns of the dorsal innervation of the foot with a lower percentage of type I pattern in European studies compared with studies in Asia<sup>13</sup>. Data of race and sex of the specimens studied could not be obtained, so we do not know if this aspect could have influenced the final results obtained and the comparison with other studies could be more complex. Secondly, measurements were carried out manually with a ruler in millimeters by a same researcher without using any instrument calibrated or tested in its reliability which could add biases or inaccuracies to the measurements of the study. Finally, the measurements of the present study were made in millimeters without any normalization to the size of the foot. One could wonder if the measurement in percentages of measurement like the one used in the study of Patel et al.<sup>13</sup>, where they take as reference specific anatomical segments such as the length of the fibula, could have been more useful from the technical point of view, (eg: the 9.81 cm calculated on average between the tip of the lateral malleolus and the perforation point of the superficial peroneal nerve could be very different between an individual of 190 cm in height and another of 150 cm) what may call into question the usefulness of these measurements in the clinical context.

In conclusion, there is controversy in the literature regarding the dorsal innervation of the foot, its anatomical variants and its frequencies and the present study provides more data and bibliography in this regard. In the present series, the data found that 48.89 % (95 % CI of 33.70 % to 64.08 %) of cases had a type I distribution (superficial peroneal nerve perforates the deep fascia and later divides into medial dorsal cutaneous nerve and intermediate dorsal cutaneous nerve), 33.33 % (95 % CI from 19.01 % to 47.66 %), a type II distribution (superficial peroneal nerve is divided into intermediate dorsal cutaneous nerve and medial dorsal cutaneous nerve on the anterior deep compartment of the leg before perforating the deep fascia and then the two nerves perforate the fascia as two independent structures) and 17.78 % (95 % CI from 6.16 % to 29.39 %) had a type III distribution (peroneal nerve superficially perforates the deep fascia and continues its course in a manner similar to the medial dorsal cutaneous nerve and the intermediate dorsal cutaneous nerve is absent).

#### CONFLICT OF INTEREST

None reported.

#### FUNDING

None reported.

#### REFERENCES

1. Sarrafian SK, Kellikian AS. Nerves. En: Kellikian AS, ed. Sarrafian's anatomy of the foot and ankle: descriptive, topographical, functional. 3<sup>rd</sup> ed. Philadelphia: Walters Kluwer Lippincott Williams & Wilkins; 2011. p. 381-427.
2. Drake R, Vogl AW, Mitchell AWM, eds. Gray's anatomy for students. 3<sup>rd</sup> Ed. Philadelphia: Elsevier; 2015.
3. Moore KL, Dalley AF, Agur AM, eds. Clinically Oriented Anatomy. 7<sup>th</sup> Ed. Philadelphia: Lippincott Williams & Wilkins; 2014.
4. Thompson A. Second Annual Report of the Committee of Collective Investigation of the Anatomical Society of Great Britain and Ireland for the year 1890-1891. *J Anat Physiol.* 1891;26(Pt 1):76-90.
5. Solomon LB, Ferris L, Tedman R, Henneberg M. Surgical anatomy of the sural and superficial fibular nerves with an emphasis on the approach to the lateral malleolus. *J Anat.* 2001;199(Pt 6):717-23.
6. Kosinski C. The course, mutual relations and distribution of the cutaneous nerves of the metazonal region of the leg and foot. *J Anat and Physiol.* 1926;60(Pt 3):274-97.
7. Ucerler H, Ikiz A. The variations of the sensory branches of the superficial peroneal nerve course and its clinical importance. *Foot Ankle Int.* 2005;26(11):942-6. DOI: 10.1177/107110070502601108.
8. Canovas F, Bonnel F, Kouloumdjian P. The superficial peroneal nerve at the foot. Organization, surgical applications. *Surg Radio Anat.* 1996;18(3):241-4.
9. Aktan Ikiz ZA, Ucerler H. The distribution of the superficial peroneal nerve on the dorsum the foot and its clinical importance in flap surgery. *Foot Ankle Int.* 2006;27(6):438-44. DOI: 10.1177/107110070602700609.
10. Blair LM, Botte MJ. Surgical anatomy of the superficial peroneal nerve in the ankle and foot. *Clin Orthop Relat Res.* 1994;305:229-38.
11. Sayli U, Tekdemir Y, Cubuk HE, et al. The course of the superficial peroneal nerve: an anatomical cadaver study. *Foot Ankle Int.* 1998;4:63-9.
12. Pacha A, Carrera A, Llusa M, Permanyer E, Molona O, Morro R. Clinical anatomy of the superficial peroneal nerve in the distal leg. *Eur J Anat.* 2003;7(Suppl. 1):15-20.
13. Tomaszewski KA, Graves MJ, Vikse J, Pękala PA, Sanna B, Henry BM, et al. Superficial fibular nerve variations of fascial piercing: A meta-analysis and clinical consideration. *Clin Anat.* 2017;30(1):120-5. DOI: 10.1002/ca.22741.
14. Tomaszewski KA, Henry BM, Ramakrishnan PK, Roy J, Vikse J, Loukas M, et al. Development of the Anatomical Quality Assurance (AQUA) Checklist: guidelines for reporting original anatomical studies. *Clin Anat.* 2017;30(1):14-20. DOI: 10.1002/ca.22800.
15. World Medical, Assembly. Declaration of Helsinki. Ginebra, Suiza: World Health Organization; 1964.
16. Drizenko A, Demondion X, Luyckx F, Mestdagh H, Cassagnaud X. The communicating branches between the sural and superficial peroneal nerves in the foot: a review of 55 cases. *Ser Radiol Anat.* 2004;26(6):447-52. DOI: 10.1007/s00276-004-0264-9.
17. Jeong SK, Paik DJ, Hwang YI. Variations in Sural nerve Formation Pattern and distribution on the dorsum or the foot. *Clin Anat.* 2017;30(4):525-32. DOI: 10.1002/ca.22873.
18. Adkinson DP, Bossem J, Gaccione DR, Gabriel KR. Anatomical variations in the course of the superficial peroneal nerve. *J Bone Joint Surg Am.* 1991;73(1):112.
19. Ramakrishnan PK, Henry BM, Vikse J, Roy J, Saganiak K, Mizia E, et al. Anatomical variations of the formation and course of the sural nerve: A systematic review and meta-analysis. *Ann Anat.* 2015;202:36-44. DOI: 10.1016/j.aanat.2015.08.002.